

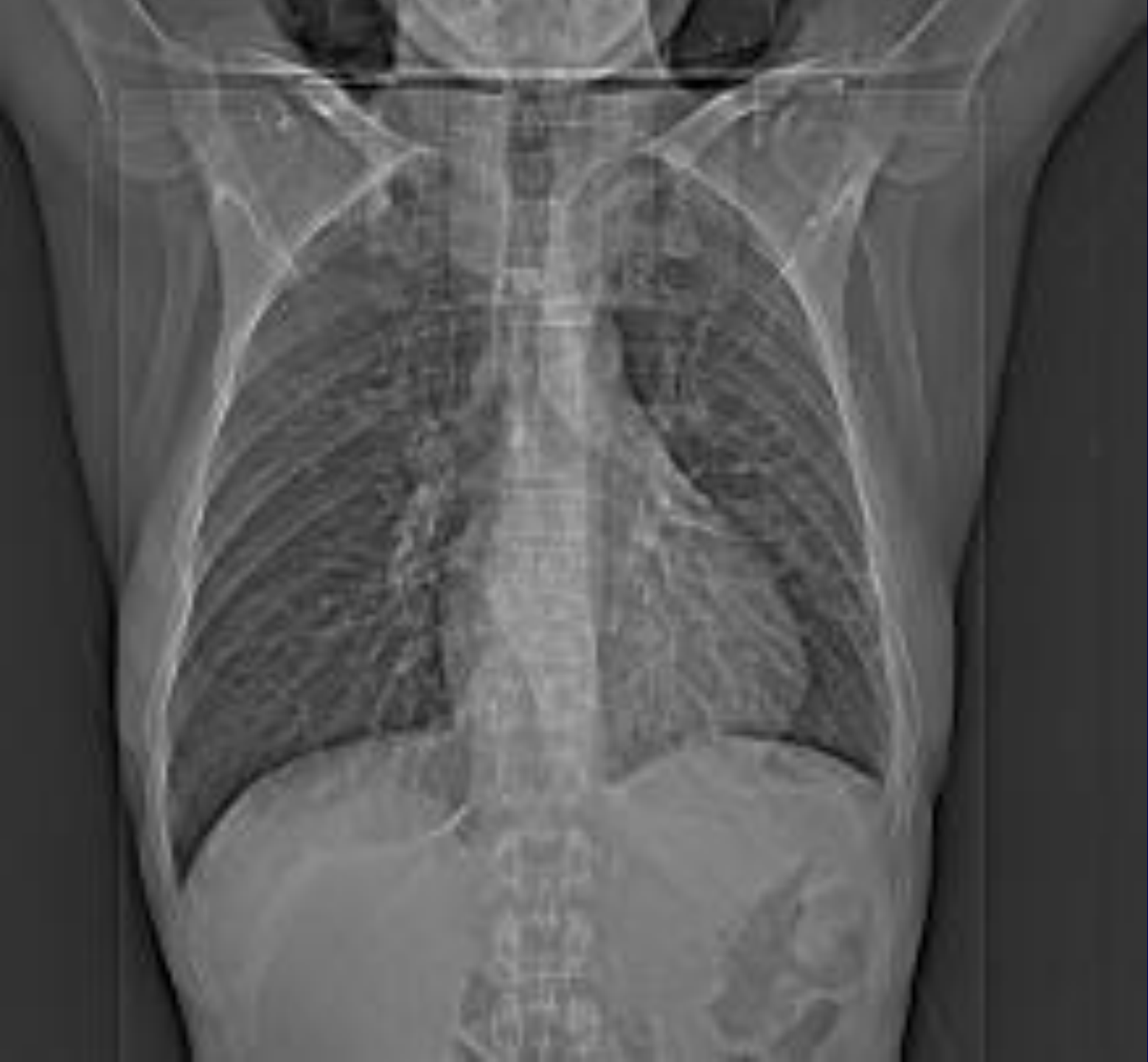

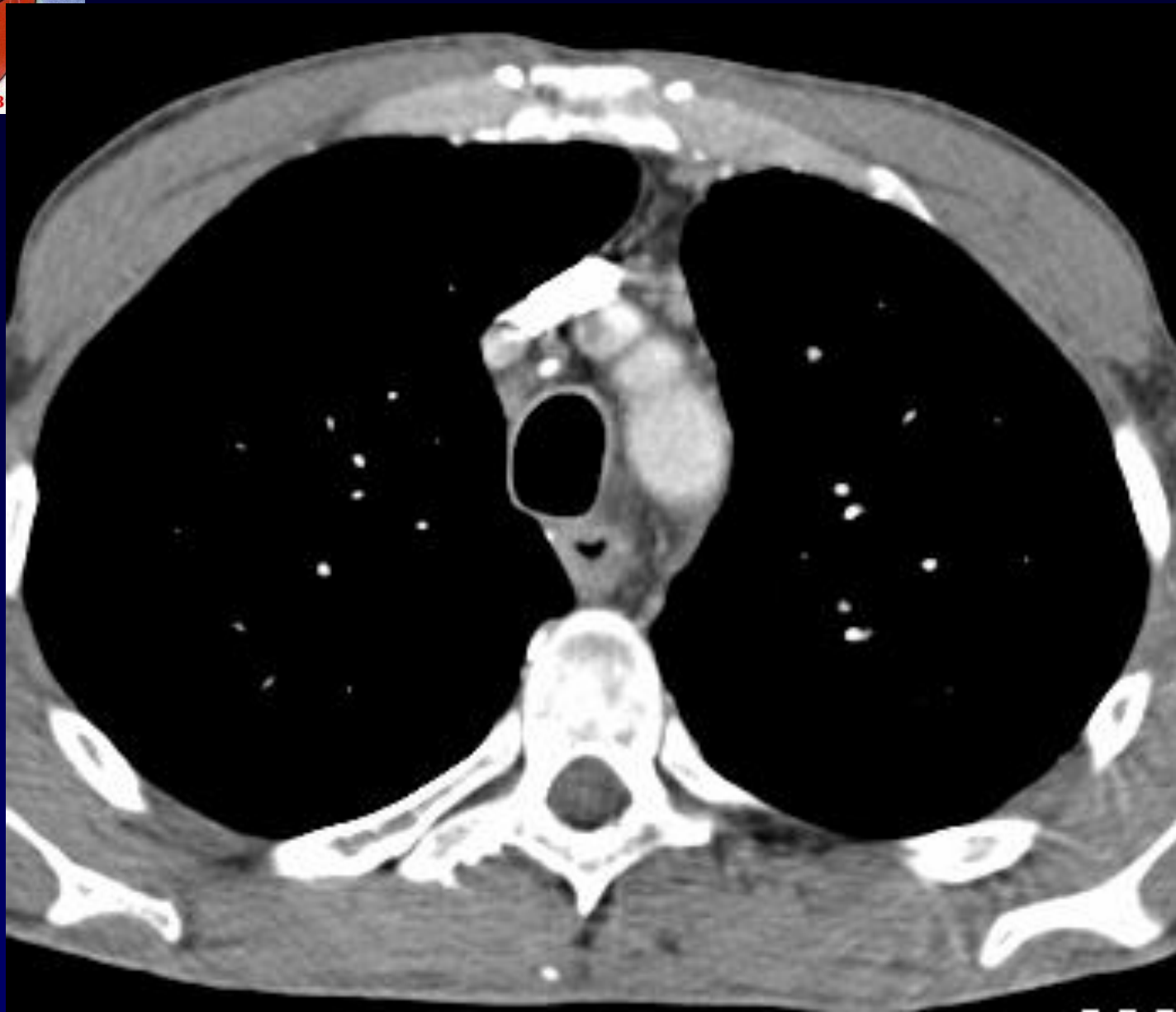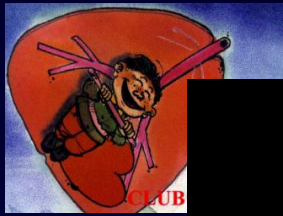J.GIRON - P.FAJADET

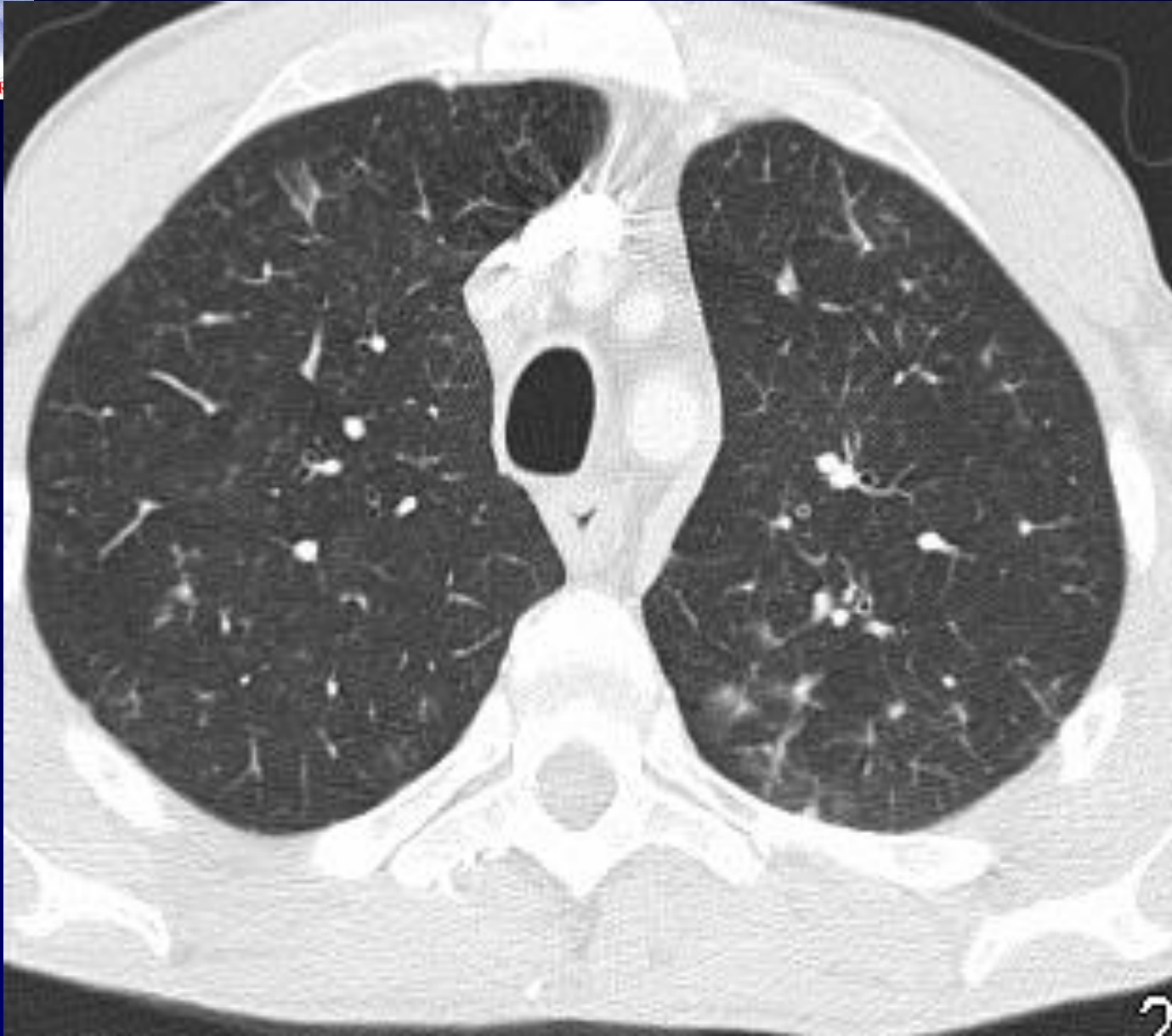
Homme de 30 ans

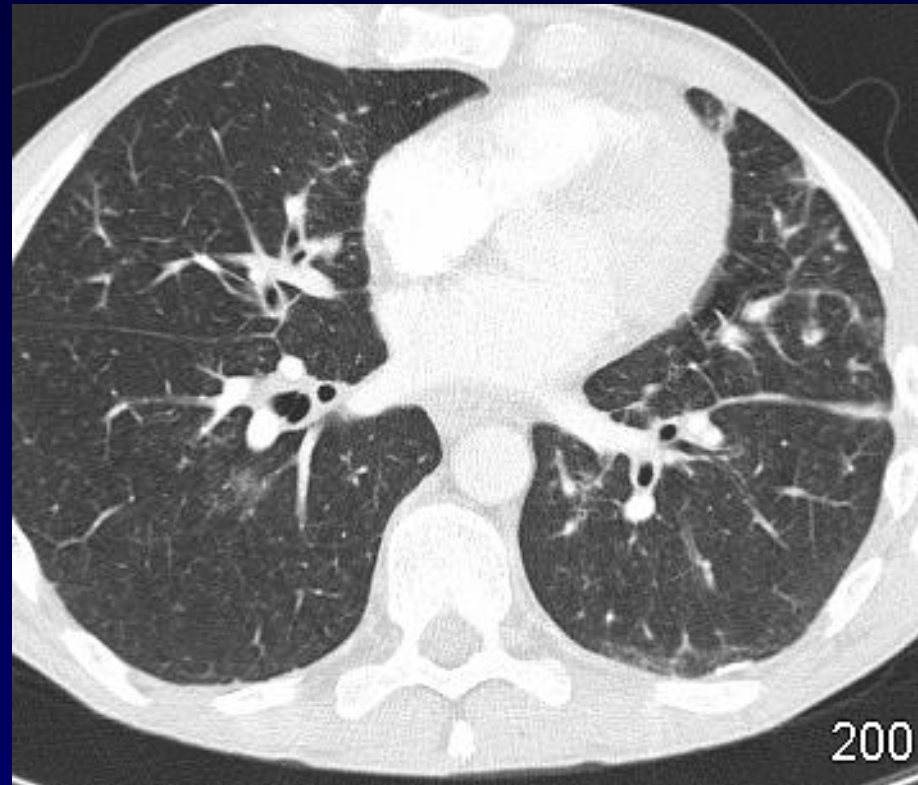
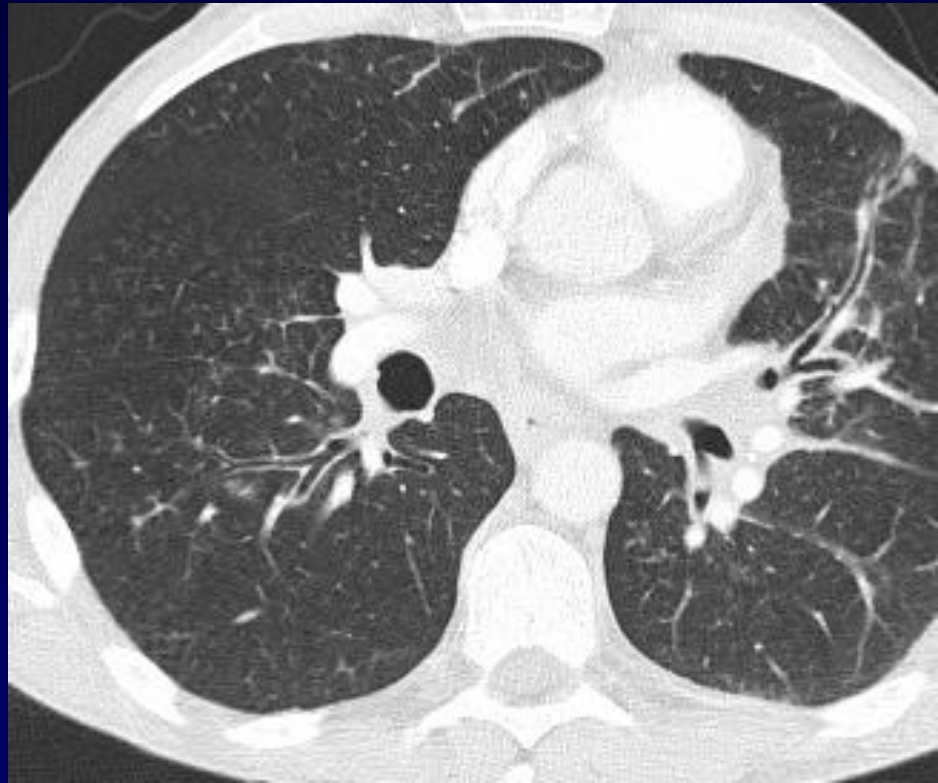

Clinique : VIH en rupture de traitement

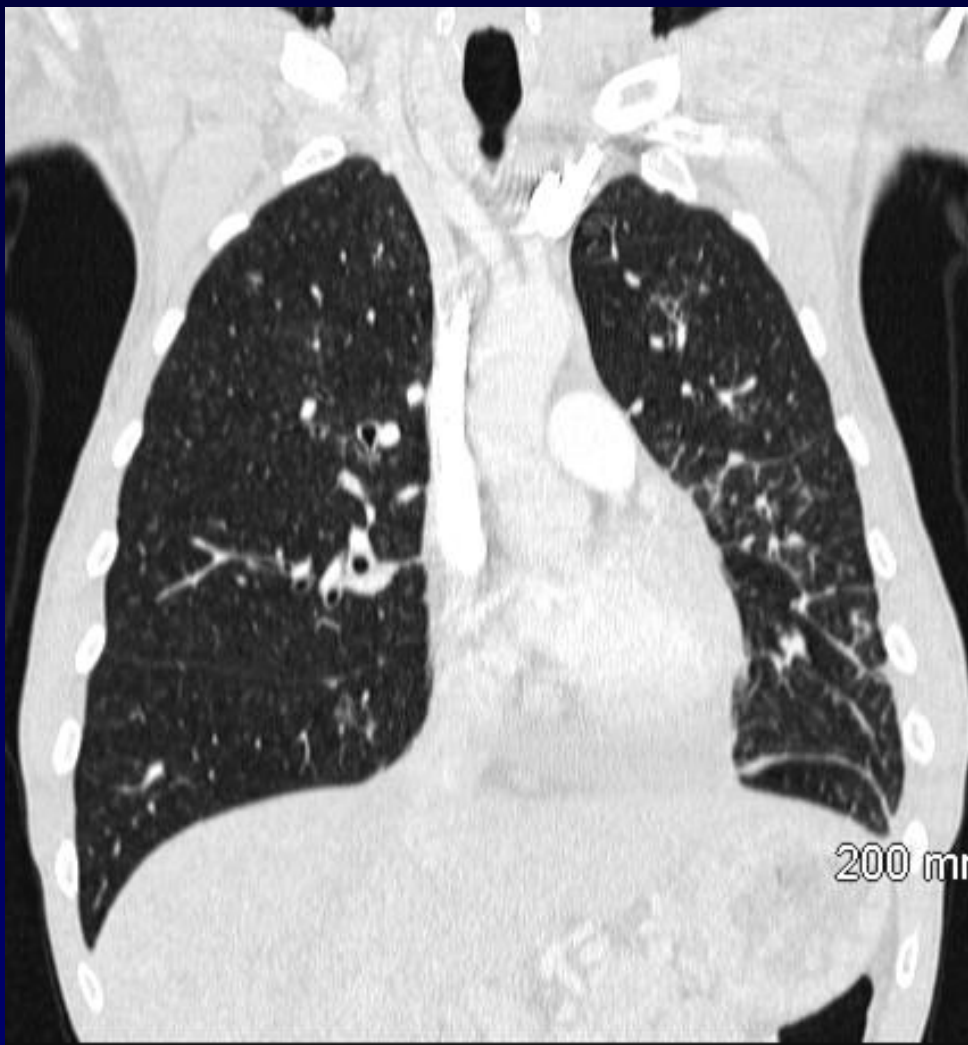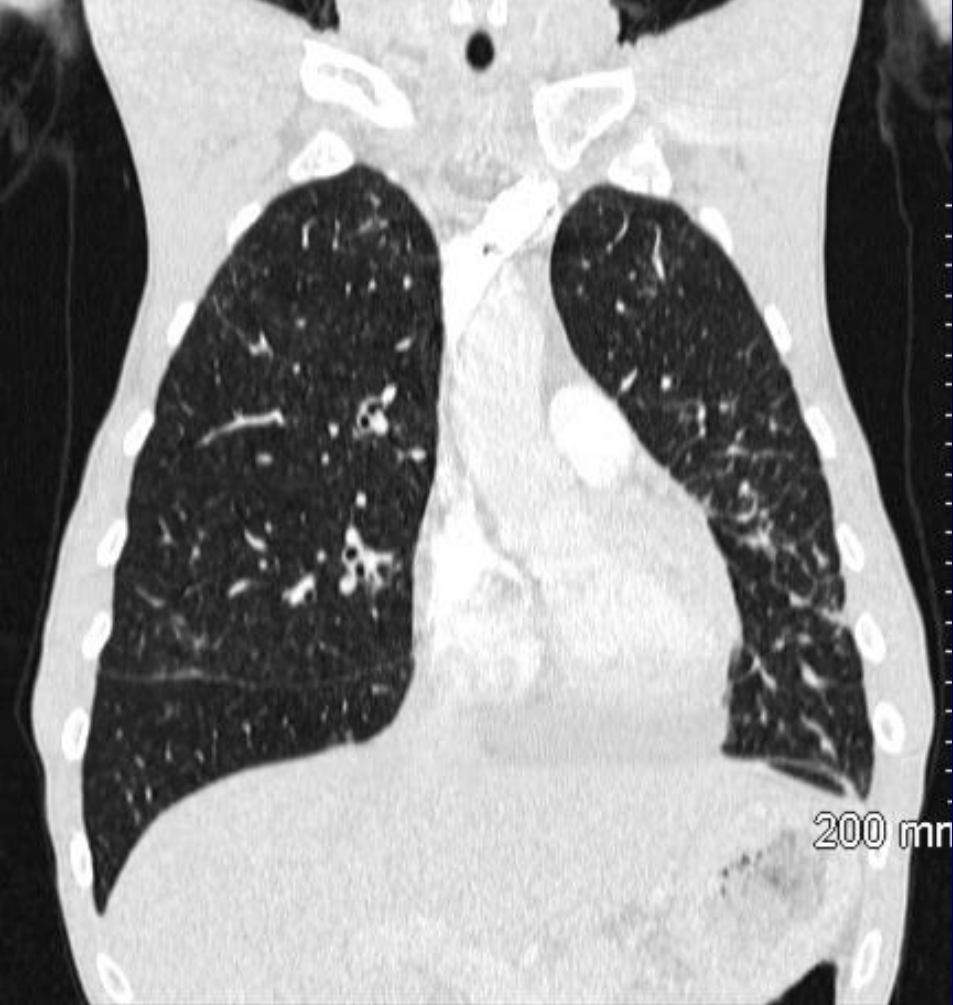Muqueuse jugale « anormale »

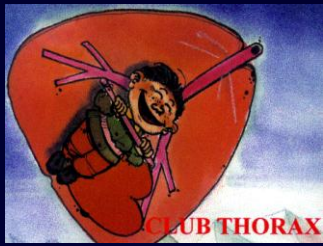




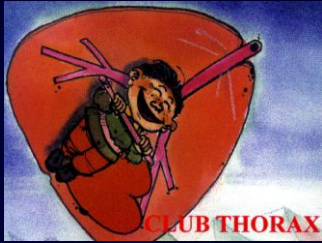








Diagnostic ?



Diagnostic

Kaposi endo bronchique

(endoscopie faite a postériori et positive)

Kaposi jugal... mais pas de symptomatologie pulmonaire